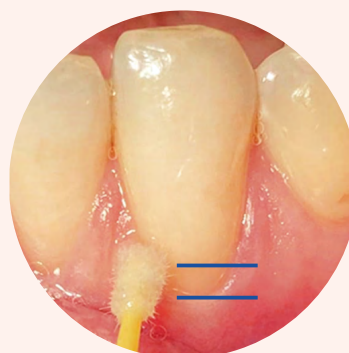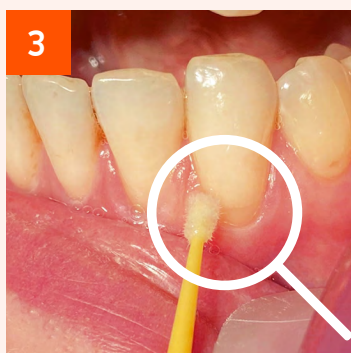
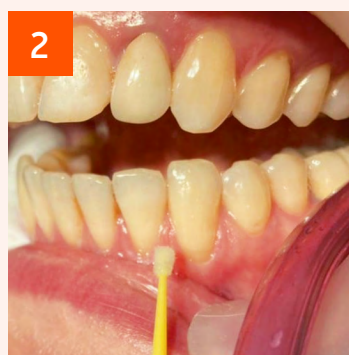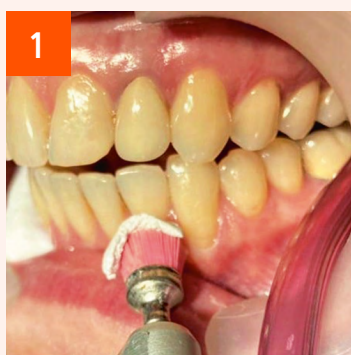


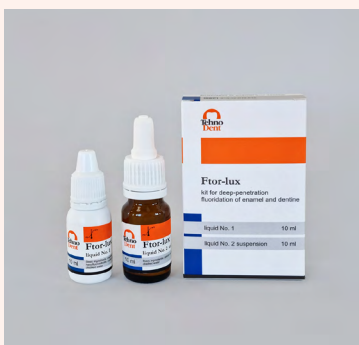

Poliren No.2, Ftor-lux kit



Gingival recession of about 3 mm

A 36-year-old woman. The patient has complaints about sudden severe pain from temperature irritants in the cervical area of tooth 3.3

- 1 — treat the teeth with Poliren No. 2 paste (fluoride-free) for polishing tooth enamel
- 2 — dry the tooth enamel with a warm air flow, apply Ftor-lux Liquid for deep fluoridation and wait for 30 seconds
- 3 — apply Ftor-lux Suspension for deep fluoridation to the teeth and rub well for 30 seconds, then rinse the teeth with water

Recommendations:

We repeated the treatment after a week. The patient noted the absence of hyperesthesia in response to thermal stimuli in the area of tooth 3.3

We would like to express our gratitude to Zinaida Aimaletdinova, Dentist, assistant at the Department of Propedeutics of Dental Diseases, RUDN University