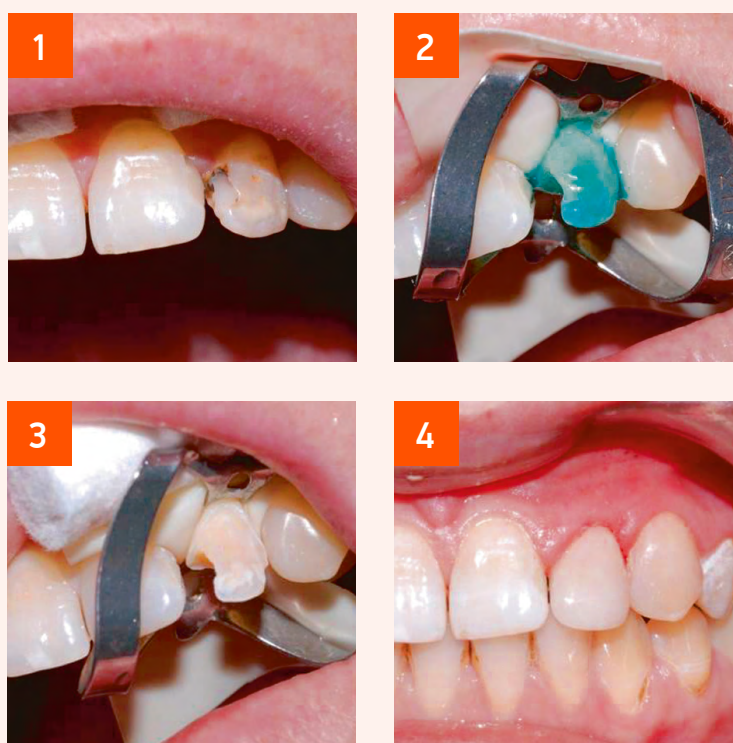
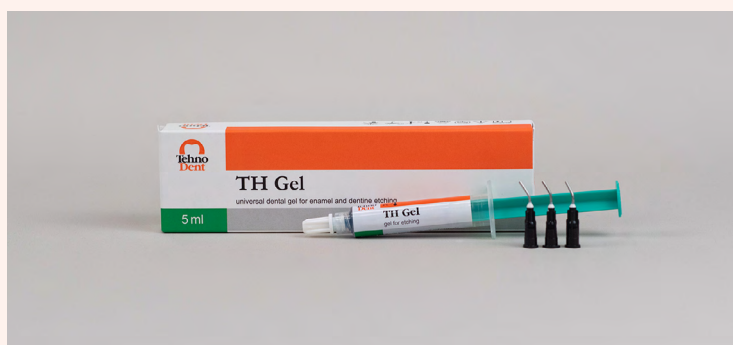



## TH Gel



Patient V., 25 years old, is not satisfied with the appearance of tooth 22. As a result of the examination, the diagnosis was made: average caries of tooth 22. The photo shows the main stages of restoration of tooth 22.

- 1 — initial situation
- 2 — etching of prepared tooth surface by TH Gel
- 3 — surface became ivory
- 4 — final result of restoration

### Expert comment

TH Gel has efficient consistency, which provides point application and effect only on specified for etching surface without leakage or material shift from the surface during etching time

Research details are kindly provided by A. Leosh and M. Iiyn ("Stomatologiya LEOSH" Ltd, Syktyvkar) and M. Parhachev ("Dent-Master" Syktyvkar)